VEXAS syndrome: a comprehensive review of pathogenesis, clinical spectrum, and therapeutic strategies

Emma M Groarke, Benjamin Turturice, Bhavisha A Patel, Kaitlin A Quinn, Alice Fike, Peter C Grayson

Vacuoles, E1 enzyme, X-linked, autoinflammatory, somatic (VEXAS) syndrome is a monogenic disease of adulthood characterised by treatment-refractory systemic inflammation and progressive bone marrow failure. VEXAS syndrome is caused by acquired mutations in the *UBA1* gene that are restricted to haematopoietic cells. Men aged 50 years or older are particularly susceptible to VEXAS syndrome, with prevalence estimates of approximately one in 4000 men. Perturbation of UBA1, the master enzyme of cellular ubiquitination, promotes myeloid-driven inflammation that is difficult to control with medications other than glucocorticoids. Cytokine-directed therapies (ie, IL-6 and JAK inhibitors) might temporise symptoms and allow glucocorticoid reduction. Hypomethylating agents (ie, azacytidine) can induce clinical and molecular remission in some patients, but are associated with substantial toxicities. Haematopoietic cell transplant might be effective treatment in patients who are suitable candidates. The discovery of VEXAS syndrome highlights the potential role of somatic mutations in complex inflammatory diseases.

Lancet 2026; 407: 637–48

Published Online January 8, 2026 https://doi.org/10.1016/S0140-6736(25)02164-6

Hematology Branch, National Heart, Lung, and Blood Institute, National Institutes of Health, Bethesda, MD, USA (E M Groarke MD, B A Patel MD); **National Institute of Arthritis and Musculoskeletal and Skin Diseases, National Institutes of Health, Bethesda, MD, USA** (B Turturice MD, K A Quinn MD, A Fike NP, P C Grayson MD)

Correspondence to: Dr Peter C Grayson, Hematology Branch, National Heart, Lung, and Blood Institute, National Institutes of Health, Bethesda, MD 02982, USA **peter.grayson@nih.gov**

Discovery of VEXAS syndrome and disease epidemiology

Vacuoles, E1 enzyme, X-linked, autoinflammatory, somatic (VEXAS) syndrome was first reported in 2020 after the analysis of peripheral blood exome sequence data collected from patients with various inflammatory diseases at the National Institutes of Health (NIH).[1] Novel somatic *UBA1* variants at the same codon, methionine-41, were shared by three of 2560 people. These three patients were older men with progressive and severe treatment-refractory systemic inflammation with cytopenia. Cutaneous, pulmonary, ocular, cartilaginous, and vascular inflammation; macrocytic anaemia; and other cytopenia, are now recognised as the hallmark clinical features of VEXAS syndrome. Somatic mutations restricted to the haematopoietic system at specific locations within *UBA1* genetically define the disease.

As a newly discovered disease, the epidemiology of VEXAS syndrome is rapidly evolving. VEXAS syndrome predominantly presents in men aged 50 years or older. As VEXAS syndrome is caused by acquired mutations in *UBA1*, an X-linked gene, women are likely protected against the disease. Large cohorts describe a male prevalence of almost 100%.[2–4] However, VEXAS syndrome has been reported in women with Turner syndrome or age-related X monosomy, and also in women with normal karyotype.[5] VEXAS syndrome is severe and life-threatening, associated with significant morbidity, and has estimated mortality rates of 30–50% at 5 years.[3,6] Among patients with missense variants at codon 41—which are the canonical mutations of VEXAS—those with the p.Met41Val variant are at highest risk for mortality and those with the p.Met41Leu variant have a less severe phenotype.[3,6] Causes of death are linked to severe inflammation, infection, bone marrow failure, and treatment-related comorbidity, especially from cumulative glucocorticoid exposure.[2,7] With sequencing of the full *UBA1* gene, non-canonical variants not occurring at the codon 41, with a predominant hematologic phenotype, have also been reported.

Patients with VEXAS syndrome have various manifestations that mimic clinically defined diseases, including relapsing polychondritis, multiple forms of systemic vasculitis, and myelodysplastic syndrome (figure 1).[1] One cohort study sequenced 92 patients who met diagnostic criteria for relapsing polychondritis and identified seven (8%) patients with VEXAS syndrome, all of whom were aged 45 years or older with cytopenia, in addition to chondritis features.[8] Cohort-based studies that have sequenced patients with giant-cell arteritis or other forms of vasculitis have rarely detected cases of VEXAS syndrome, suggesting that these patients are rarely misdiagnosed.[9] A study of 3323 patients with myelodysplastic syndrome found pathogenic *UBA1* variants in 40 (1%) of the total cohort.[10] In a subgroup of 375 male patients without typical myelodysplastic syndrome (ie, unclassifiable or with myeloproliferative neoplasms),[10] 28 (7%) men had $UBA1^{mut}$ detected.[10]

Population genetic studies provide prevalence estimates for VEXAS syndrome and suggest potential for an expanding clinical spectrum of disease. The incidence of VEXAS syndrome is unknown, but cases have been reported worldwide. Data collected within the Geisinger Health System estimate the prevalence of VEXAS syndrome to be one in 13 591 adults and one in 4269 men age 50 years or older. The data suggested complete penetrance of disease in patients with known pathogenic $UBA1^{mut}$.[11] A study conducted using the All of Us Research

Search strategy and selection criteria

We searched MEDLINE, PubMed, Embase, and Web of Science for articles published between Dec 31, 2020 (when VEXAS syndrome was first described), and Aug 1, 2025, using the search term "VEXAS". Only articles in English were considered. We also searched the reference lists of articles identified through this search strategy and selected those we judged relevant. Case reports and case series with less than five patients were excluded.

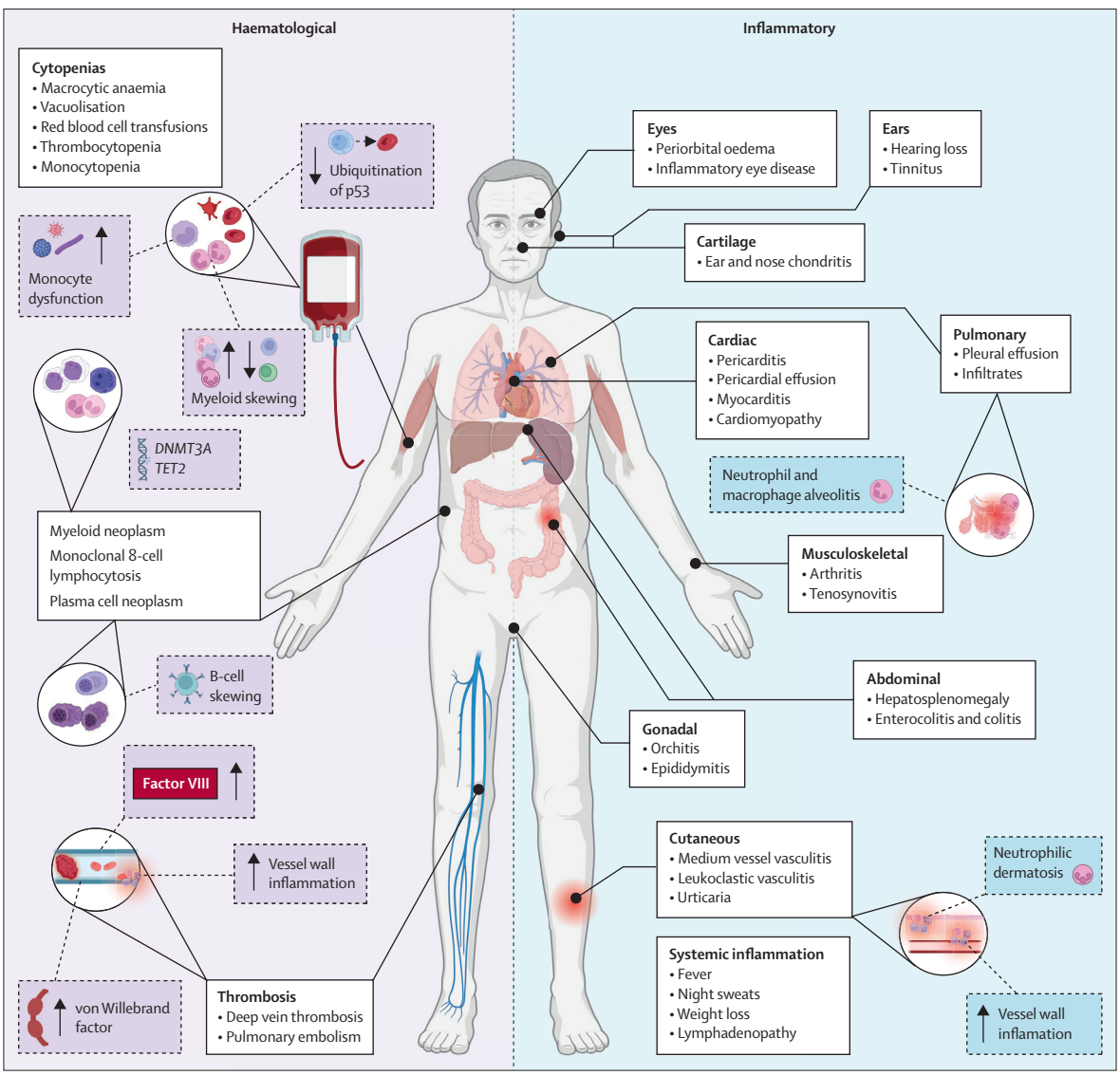

Figure 1: **Overview of VEXAS syndrome**
VEXAS syndrome is a multisystemic disease affecting most organs. The clinical phenotype is expanding and the pathobiology of some manifestations have been elucidated. VEXAS=vacuoles, E1 enzyme, X-linked, autoinflammatory, somatic.

Program—a population of community-dwelling individuals who might be healthier than participants in hospital-based cohorts—identified 74 of 245 368 participants with pathogenic *UBA1*^{mut}, which included 62 women (84% of those with *UBA1*^{mut}).[12] These patients were typically younger than patients with VEXAS syndrome with lower clonal burden of *UBA1*^{mut} in blood. Although direct clinical evaluation was not performed, there were no differences in diagnostic codes between *UBA1* carriers and control participants, suggesting incomplete disease penetrance or preclinical disease state. Another population-based study reported that people with *UBA1* variants at lower variant allele frequencies (VAF) can be initially asymptomatic and develop disease later.[13] Together, these studies highlight that *UBA1* mutations are more prevalent than expected and might have an evolving clinical phenotype that is under-recognised and less penetrant in women. Disease detection in diverse patient populations and in preclinical states is an area of high importance and ongoing investigation.

Pathophysiology of VEXAS syndrome

VEXAS syndrome is caused by somatic hypomorphic mutations of the E1-enzyme, *UBA1,* in haematopoietic stem cells.[1] Patients with VEXAS syndrome share phenotypic presentations with patients with other genetic disorders of the ubiquitin-proteasome system (ie, autoinflammation, panniculitis, and dermatosis syndrome caused by germline variants in *OTULIN*),[14] and exhibit perturbed haematopoietic cellular

composition and survival, autoinflammation, and immunodeficiency caused by loss of typical cellular ubiquitination.

UBA1 isoforms are generated from two alternative start sites with the p.Met1 start site producing a larger nuclear isoform (UBA1a; 117 kDa) containing an N-terminal nuclear localisation sequence, and the p.Met41 start site producing the smaller cytoplasmic enzyme (UBA1b; 110 kDa).[15] The ratiometric quantities of UBA1a and UBA1b are regulated throughout cellular differentiation and division.[16–18] Two broad categories of acquired variants have been reported: canonical mutations that result in reduced quantity of UBA1b and non-canonical mutations that reduce the enzymatic function of UBA1.[19] These mutations result in substantial reductions in cellular levels of ubiquitination—a process essential for protein degradation, localisation, and signaling,[20] consistent with findings that UBA1 is the main enzyme responsible for conjugating ubiquitin to E2 enzymes.[21] Disease activity has been linked to residual translation of UBA1b, with the p.Met41Val variant supporting less UBA1b translation than either p.Met41Leu or p.Met41Thr, potentially contributing to the increased clinical disease severity observed with p.Met41Val.[6]

Canonical mutations are point mutations occurring predominantly in the methionine-41 codon and reduce usage of that codon as a start site, with the alternative start site of p.Met67 producing catalytically inactive UBA1c.[1] Differences between p.Met41 variants have been well characterised, with p.Met41Val producing the least UBA1b translation and is associated with a more severe phenotype.[2,3,6] Mutations have also been described at the splice acceptor site c.118, leading to truncation and frameshift of *UBA1* mRNA with loss of the Met41 codon.[22] These mutations lead to substantially reduced UBA1b with maintenance of UBA1a.[6] By contrast, non-canonical mutations have been reported primarily in the active adenylation domain,[19,23–27] with in vitro models showing reduced cellular ubiquitination through loss of E1 to E2 enzyme transfer of ubiquitin. A haematological phenotype in non-canonical variants has been reported;[27] however, given the lower prevalence than canonical variants, phenotypic differences are more equivocal than the differences between Met41 variants.[19,26]

UBA1 somatic mutations can occur in isolation or can co-occur with other haematopoietic clones. In most cases, *UBA1*^{mut} VAF is high (>20%) in both peripheral and bone marrow samples.[7] Patients with low *UBA1* VAF (<20%) were found to have less disease penetrance and, when symptomatic, have decreased rates of macrocytic anaemia and reduced glucocorticoid requirements. Multiple mechanisms for *UBA1*^{mut} clonal persistence and predominance have been proposed based on a humanised murine model, including increased cellular senescence in *UBA1*^{mut} haematopoietic stem cells, and cytokine mediated suppression of unmutated haematopoietic stem cells.[28] *UBA1* mutations are observed in the myeloid lineage and, to a lesser degree, in megakaryocyte and erythroid progenitors.[1,28] Differentiating lymphoid cells are intolerant to *UBA1*^{mut}, whereas erythroid and megakaryocytic cells are partly tolerant.[29–31] Additional shifts in immune population include loss of CD16^{+}CD14^{-} and HLA-DR^{+} monocytes, dendritic cells, CD56^{+} natural killer cells, and transitional and naive B cells.[1,32] Furthermore, increased clonality in CD8^{+} T cells has been observed without clear evidence of a specific antigen-driven process common across patients.[33] The prevalence of specific cytopenia, such as monocytopenia, lymphopenia, anaemia and thrombocytopenia, is dependent on disease duration and *UBA1*^{mut} variant.[2]

At the cellular level, *UBA1*^{mut} cause increased activation of the unfolded protein response and endoplasmic reticulum-associated protein degradation pathways with increased PKR/ATF4 and IRE1a/XBP1 in vitro signalling in zebrafish, murine, and human samples.[1,28,33–35] This activation is correlated with levels of inflammatory pathways upregulated in patients with VEXAS syndrome.[33] Activation of these pathways by VEXAS syndrome-defining mutations has been shown to cause myeloid bias in haematopoietic stem cells.[33,34]

Patients with VEXAS syndrome have significant increase in multiple inflammatory pathways in both mutated and unmutated haematopoietic cells, with upregulation of genes involved in IL-1, IL-6, IL-18, TNF, and interferon signalling in serum, bone marrow, peripheral blood, and skin.[1,28,32,33,36,37] These pathways are predominantly overexpressed in the myeloid compartment, although INFγ-stimulated genes are upregulated in natural killer and CD8^{+} T cells.[32] Although increased spontaneous production of TNF by bone marrow mononuclear cells has been reported, increased cytokine production in response to microbial stimulation has been inconsistent and other functions, such as phagocytosis, might be impaired.[33,37] Additionally, increased upregulation of S100A proteins, particularly S100A8 and S100A9, has been reported.[28,37] These proteins function not only as antimicrobial, but also as damage-associated molecular patterns that can cause persistent inflammation.[38] Compared with healthy controls, VEXAS myeloid cells have heightened expression of genes associated with cell death, caspase 1/3/7 activation, and increased inflammatory and non-inflammatory cell death.[39] In patients with VEXAS syndrome, damage-associated molecular patterns are increased in serum, neutrophils undergo spontaneous NETosis, and IL-18 is increased in serum, suggestive of increased inflammatory cell death as perpetuating systemic inflammation.[1,37,39] Dysregulation of such a broad array of inflammatory pathways in VEXAS syndrome is consequence of unfolded protein response, NF-κB, and inflammasome activation influenced by dysregulated ubiquitination.

Despite heightened inflammatory state, patients with VEXAS syndrome are susceptible to various microbial

pathogens. Although cytopenias and chronic immunosuppression might have a role in susceptibility, patients also have increased risk of intracellular infections, such as *Legionella pneumophila* and non-tuberculosis mycobacterium.[40–44] Many intracellular pathogens have virulence factors that modulate cellular ubiquitination, such as DupA and DupB deubiquitinases in *Legionella* spp.[45,46] Additionally, deficiency of E3 ubiquitin ligases increases susceptibility to multiple intracellular pathogens.[47] Therefore, patients might have intrinsic susceptibility to specific infections, as well as be at risk for iatrogenic infections due to chronic immunosuppression.

Diagnosis and inflammatory features of VEXAS syndrome

Although there are no diagnostic or classification criteria for VEXAS syndrome, a diagnosis generally requires genetic confirmation of a known pathogenic *UBA1* variant with supporting features of disease (ie, systemic inflammation or cytopenias). Options for genetic screening include targeted testing for exon 3 variants in *UBA1* or next-generation sequencing testing of the entire gene. Mutations can be readily detected in bone marrow or peripheral blood. Older patients, particularly men, with recurrent inflammation of skin, eyes, cartilage, or lungs should strongly be considered for testing, especially with associated macrocytosis or macrocytic anemia.[48] Systemic screening for *UBA1* in patients with myelodysplastic syndrome should also be strongly considered, including men with unclassifiable or myeloproliferative neoplasm myelodysplastic syndrome; isolated mutations in *DNMT3A*, *TET2*, or *ASXL1*; or co-occurring inflammatory clinical features.

The inflammatory manifestations of VEXAS syndrome are multisystemic, and the classic phenotype includes constitutional, cutaneous, cartilaginous, musculoskeletal, pulmonary, and ophthalmologic symptoms that fluctuate (figure 2).[1] Illness onset generally begins with cutaneous lesions and mild constitutional symptoms, including low-grade fever, fatigue, malaise, and anorexia, progressing to high-grade fevers with night sweats and substantial weight loss. Laboratory abnormalities reflect systemic inflammation with highly increased acute phase reactants, macrocytic anaemia that is often more severe with active disease, and non-specific autoimmune serological positivity that can lead to diagnostic delay.[2] Patients might present with recurrent bouts of microbiologically negative cellulitis or pneumonia, which are in fact VEXAS syndrome flares.

The three largest VEXAS syndrome cohorts reported more than 80% prevalence of cutaneous involvement.[3,49,50] Lesions appear with flare activity and in 45–63% of patients are the initial clinical manifestation.[49,51] Cutaneous lesions are heterogeneous with papular, arcuate plaques; nodular, pustular, urticarial, vasculopathic, or purpuric lesions commonly affecting the torso, extremities, and face; while the acral–palmoplantar, intertriginous, and scalp surfaces usually remain unaffected. Histological examination generally shows neutrophilic dermatosis, septal panniculitis, and leukocytoclastic vasculitis. An association between *UBA1* genotype and cutaneous phenotype was reported showing p.Met41Leu with more frequent neutrophilic dermatosis and p.Met41Val with more frequent purpuric and petechial manifestations.[49]

Pulmonary manifestations involving the parenchyma or pleura are present in 44–66% of patients, including ground-glass opacities, nodular infiltrates, consolidations,

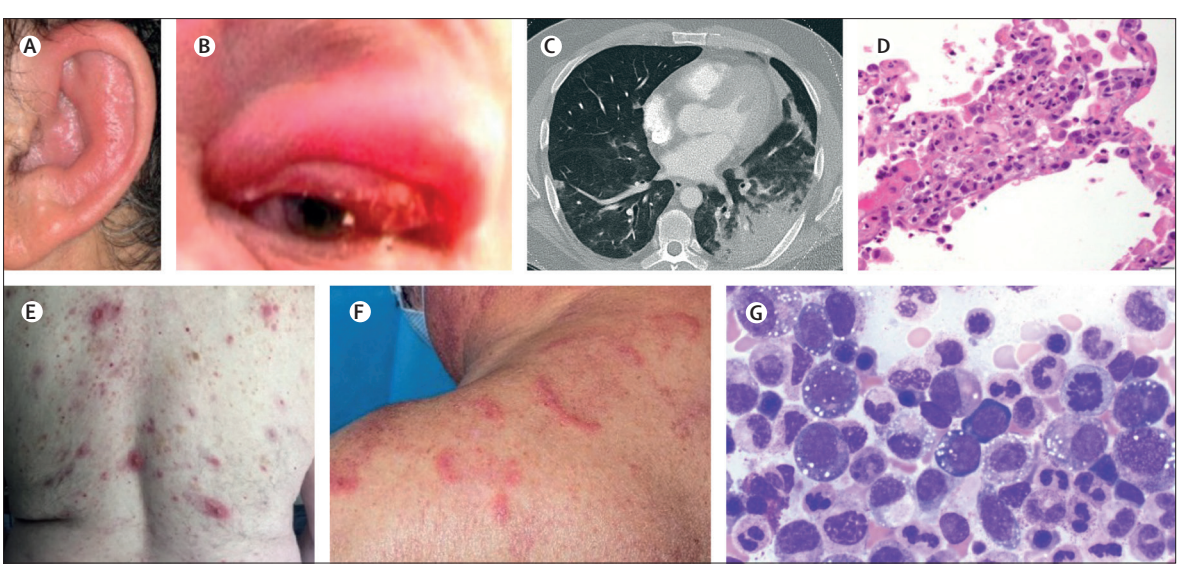

Figure 2: **Clinical images from patients with VEXAS syndrome**
(A) Cartilaginous involvement includes auricular and nasal chondritis. (B) Periorbital inflammation. (C) Pulmonary involvement can manifest as pleural effusion or infiltrates. (D) Histological neutrophilic alveolitis. (E) Cutaneous involvement includes Sweet's syndrome. (F) Characteristic cutaneous arcuate plaques. (G) Bone marrow is typically hypercellular with granulocytic hyperplasia, erythroid hypoplasia, and vacuolisation of myeloid and erythroid precursors. VEXAS=vacuoles, E1 enzyme, X-linked, autoinflammatory, somatic.

and exudative effusions.[52–55] Radiographic abnormalities due to inflammation are reversible, recur with subsequent flares, and progression to pulmonary fibrosis has not been reported.[56] Bronchoalveolar lavage of sterile pulmonary infiltrates across several cohorts ranged from typical cell differentials to a neutrophilic or macrophage predominant alveolitis.[1,52,56] A 2025 retrospective review of non-ischemic cardiac manifestations reported that eight (2·7%) of 299 patients showed cardiac involvement, including pericarditis, myocarditis, heart block, heart failure, and AA amyloidosis.[57]

Musculoskeletal manifestations include chondritis (36–50%), arthralgia and arthritis (28–58%), myalgia, and, less commonly, overt myositis and fasciitis.[3,53–55] Chondritis typically affects auricular and nasal cartilage and is non-damaging, although other cartilaginous structures can be affected.[55] Additional common clinical manifestations include orchitis and epididymitis (18–30%) and inflammatory ocular disease.[58] Periorbital oedema might be confused with periorbital cellulitis given its acuity and potential severity.[1] Including periorbital oedema, 36–64% of patients with VEXAS syndrome might have ocular inflammation, such as episcleritis, conjunctivitis, scleritis, and uveitis.[3,53,55,59,60] Orbital myositis, dacryoadenitis, and orbital inflammatory syndrome occur, but are less common. Sensorineural hearing loss and disequilibrium are frequent and possibly under-reported.

Vasculitis might be present and can mimic other autoimmune systemic vasculitis. Within a cohort of 89 patients with VEXAS syndrome, 21 (24%) had vasculitis, primarily presenting as cutaneous small-vessel vasculitis (n=17). This study also reported patients with renal capillaritis not involving the glomeruli (n=1), medium-vessel involvement of skin (n=2), and temporal artery inflammation with focal neutrophilic infiltrate (n=1).[61] Other organ involvement is rare but can be present in severe or undertreated cases, and might, in some cases, reflect vascular involvement. In one report, 11 (3·6%) of 303 patients had a kidney injury requiring biopsy; histology included primary acute interstitial nephritis, glomerulonephritis, and acute tubular necrosis.[62] A systematic review of 710 patients with VEXAS syndrome reported renal involvement in 19 (7%) of 270 patients, and identified rates of colitis in seven (3·1%) of 226 patients, and peripheral nervous system involvement in 29 (7·1%) of 410 patients.[63] Some additional clinical manifestations might be iatrogenic, such as gastrointestinal perforation or bleeding.

VEXAS syndrome can mimic a spectrum of clinical diseases, such as antineutrophil cytoplasm antibody-associated vasculitis, biopsy-negative giant-cell arteritis, and inflammatory bowel disease. VEXAS syndrome has also been reported to cause Castleman disease-like changes in lymph nodes, with Philip and colleagues[64] reporting the mimicking of multicentric Castleman disease. Specific *UBA1* genotypes might influence phenotype. Chondritis that mimics relapsing polychondritis is prevalent, particularly among patients with the p.Met41Thr variant, the most common variant in VEXAS.[8,65] The p.Met41Val variant is notable for more intense systemic inflammation and accelerated progression to bone marrow failure. Regarding skin involvement, Sweet's syndrome has been associated with p.Met41Leu, whereas p.Met41Val has been associated with vasculitic lesions.[6,49]

Atypical infections from intracellular pathogens, which are often difficult to differentiate from inflammatory symptoms, should be considered due to immune deficiency secondary to *UBA1*^{mut}, as well as bone marrow failure, inflammation in barrier mucosa, iatrogenic immunosuppression, and older age.[42] SARS-CoV-2, *Legionella* pneumonia, *Pneumocystis jirovechii* pneumonia, herpes viral reactivation, and disseminated non-tuberculous mycobacterium infections have been reported, and adversely impact survival.[40,41,66]

Haematological features of VEXAS syndrome

Haematological manifestations of VEXAS are broad and include bone marrow failure with consequent progressive cytopenia, increased risk of haematological malignancies (including myeloid neoplasia and plasma cell dyscrasia), and high thrombotic risk.

Within the spectrum of haematological involvement, cytopenia dominates. Macrocytic anaemia is almost ubiquitous, occurring in more than 95% of patients with VEXAS syndrome.[7,29] However, although macrocytosis is common, approximately 25% of patients have a mean corpuscular volume of less than 100 fL at time of symptom onset.[2] Severe anaemia with transfusion dependence and clinically significant thrombocytopenia are less common, with both conditions occurring in approximately 20–25% of patients, and have been associated with progressive bone marrow failure, myelodysplastic syndrome, and worse overall survival.[2,7] Lymphopenia and monocytopenia also occur in most patients. Neutropenia is rare, although can occur as a consequence of treatment.[2]

Bone marrow morphology typically shows hypercellularity for age with left shifted granulopoiesis and vacuolisation of myeloid and erythroid precursors.[29,30] Mild dyspoiesis is a common but non-specific finding, particularly evident in the megakaryocyte lineage.[30] Although myeloid and erythroid precursor vacuolisation is common and characteristic, it is not disease-specific, and its absence does not preclude a diagnosis of VEXAS syndrome.[67–70]

Underlying the cytopenia in VEXAS syndrome is ineffective haematopoiesis; *UBA1*^{mut} has differing direct effects on haematopoietic cell lineages and the resultant inflammatory environment also has an important role. Myeloid bias occurs early in haematopoiesis, with activation in multiple inflammatory pathways seen in haematopoietic stem and progenitor cells (HSPCs), particularly the myeloid lineage.[28,33,71] Although *UBA1*^{mut} HPSCs acquire senescence markers and can withstand this inflammatory milieu, the remaining wild-type

HSPCs are unable to support multilineage haematopoiesis, likely contributing to bone marrow failure.[28] Myeloid skewing is also likely accentuated by the lethal effect of *UBA1*^{mut} on maturing lymphoid cells, ultimately leading to lymphopenia.[1,33] Mutant *UBA1* is lethal to maturing erythrocytes, leading to cell death at the early stages of erythroid differentiation due to defective ubiquitination of p53.[72] Immune dysregulation (including secondary clonal expansion of CD8$^+$ T cells), skewed B-cell differentiation, and dysfunctional monocytes likely contributes to the immune system activation, risk of plasma cell dyscrasia, and increased infection risk seen in VEXAS syndrome.[73]

More severe haematological phenotype has been associated with specific *UBA1*^{mut} genotypes, and *M41L* has been associated with increased rates of myelodysplastic syndrome.[7] *S56F*, a pathogenic non-M41 variant, has been associated with more cytopenia, expanded erythropoiesis in the bone marrow, and less inflammatory manifestations.[74] Using whole-genome sequencing in 4168 patients with haematological malignancies, non-M41 presumed germline or somatic variants of uncertain significance across the *UBA1* gene have been detected in a range of non-myeloid haematological disorders, including non-Hodgkin lymphoma, acute lymphocytic leukaemia, chronic lymphocytic leukaemia, plasma cell dyscrasia, and autoimmune haemolytic anaemia, although the disease association remains unclear.[75]

The incidence of reported myelodysplastic syndrome has been widely varied within described VEXAS syndrome cohorts, from 20% to 55%,[1,7,23] likely due to intervariability of myelodysplastic syndrome diagnosis. Although dyspoiesis and cytopenia are commonly observed in VEXAS syndrome, *UBA1*^{mut} is the likely driver, with resultant ineffective haematopoiesis and increased marrow environmental inflammatory milieu.[7] Within the spectrum of myelodysplastic syndrome, the haematopathological, cytogenetic, and molecular features are also distinct to non-VEXAS myelodysplastic syndrome, suggesting that VEXAS–myelodysplastic syndrome is a discrete entity. Most patients have normal chromosomal karyotype and the somatic mutation profile is predominated by *DNMT3A* and *TET2* gene mutations, more associated with age-related clonal haematopoiesis or inflammation than with leukaemia.[7,10,30] Low or very low risk stratification by the revised international prognostic scoring system, commonly used to risk stratify myelodysplastic syndrome, accounts for the majority of patients with VEXAS–myelodysplastic syndrome.[7,10] High-risk myelodysplastic syndrome with increased blasts and acute myeloid leukaemia are uncommon, representing less than 10% of confirmed myeloid neoplasms in patients with VEXAS syndrome.[10] Other myeloid neoplasms, including chronic myelomonocytic leukaemia, chronic myeloid leukaemia, and other myeloproliferative neoplasms, have rarely been described in patients with VEXAS syndrome.[7,10]

Plasma cell neoplasm, primarily monoclonal gammopathy of undetermined significance (MGUS), has been reported in approximately 20% of patients with VEXAS, compared with approximately 3–5% in the healthy ageing population.[1,29,76] Most reported MGUS is IgG-κ or IgG-λ. Risk of plasma cell neoplasm might relate to the skewed B-cell differentiation with loss of transitional B cells and expansion of plasmablasts.[73] Progression to overt multiple myeloma requiring therapy also occurs in a proportion of patients with plasma cell neoplasm (~20%).[7,29] For reasons that remain unclear, most patients with VEXAS syndrome-associated multiple myeloma show the presence of t(11;14) and have increased cyclin D1 expression compared with patients with myeloma who have not received this treatment.[77]

Venous thromboembolism occurs in more than 40% of patients with VEXAS syndrome, and is likely multietiologic.[78,79] Most reported venous thromboembolism is the absence of an identifiable risk factor with high risk of recurrence, even while receiving anticoagulation treatment. High levels of factor VIII and von Willebrand factor have been reported in more than 90% and 40% of patients, respectively. Factor VIII is an acute phase reactant and might represent a response to the high degree of disease-driven inflammation to promote thrombosis. Positive lupus anticoagulant occurs in approximately 40% of patients with VEXAS syndrome, without concurrent anticardiolipin or β2 glycoprotein antibody positivity, and with a positive correlation to increased C-reactive protein. This finding suggests lupus anticoagulant positivity might be due to other factors such as inflammation, high C-reactive protein concentrations, or other assay interference, as opposed to a true antiphospholipid syndrome.[78] Other potential contributors to thrombosis include exaggerated NETosis as shown in neutrophils, activated monocytes, and direct inflammation and injury to blood vessels from vasculitis.[1,71,73,79]

Arterial thrombosis, including myocardial infarction and stroke, occurs in more than 10% of patients. Considering the high rates of cardiovascular disease in older male patients, it remains to be seen whether VEXAS syndrome is associated with a substantially increased risk for arterial thrombosis.[78]

Treatment of systemic inflammation in VEXAS syndrome

Glucocorticoids are currently the most effective medication to control systemic inflammation in patients with VEXAS syndrome; however, patients often require moderate daily doses (eg, prednisone 15–35 mg daily) to prevent disease flare.[1] Systemic inflammation can recur when glucocorticoids are tapered too rapidly or below patient-specific threshold requirements. Only in rare circumstances are patients able to fully taper off glucocorticoids without disease flare. Most patients with VEXAS syndrome require chronic glucocorticoid

treatment, which has substantial toxicities. Therefore, identification of effective steroid-sparing therapies is crucial (figure 3). In a study of 71 patients with VEXAS syndrome over a median follow-up of approximately 5 years, the mean prednisone dose was more than 15 mg/day, independent of variant or disease duration. Patients with VEXAS syndrome have increased signs of metabolic toxicity from glucocorticoids compared with patients with giant-cell arteritis (matched for age, sex, and disease duration). Absence of clinical symptoms and C-reactive protein 10 mg/L or less on prednisone 10 mg/day or less was seen in only 2·7% of patients with VEXAS syndrome.[2]

No randomised controlled trials in VEXAS syndrome have been completed and data regarding available therapies is mainly based on case series and cohort studies (table). Additionally, there remain no standardised definitions of treatment response. Although development efforts are ongoing, making direct comparisons between studies is challenging. As *UBA1*^{mut} are restricted to myeloid cells, treatments targeting the innate immune system appear to be more effective than those targeting the adaptive immune system. IL-6-directed therapies (anti-IL-6R), tocilizumab and JAK inhibitors, have been shown to be effective in controlling inflammatory symptoms.[53,94–97] Use of anti-IL-6R might be limited by cytopenia in patients with VEXAS syndrome and our practice at the National Institutes of Health allows for absolute neutrophil of $0·75\times10^9$/L and platelets of 50×10^9/L before holding drug. In approximately 5% of patients with VEXAS syndrome, a paradoxical systemic reaction to tocilizumab has been reported, which is notable for cutaneous lesions, malaise, and fever, precluding further use. Of the various JAK inhibitors, ruxolitinib is potentially the most effective, as was reported in a multicentre study of 30 patients with VEXAS. Differences in efficacy seen among JAK inhibitors might be secondary to selection bias among different cohorts, varied dosing regimens, or a true difference in target specificity.[53,84] Potential medication risks of JAK inhibitors, including cytopenia, thromboembolic disease, infections, and cardiovascular events, should be carefully considered within this population.[85] IL-1 directed therapies, including anakinra and canakinumab, have shown efficacy in some studies, but have a high discontinuation rate, often due to severe local injection site reactions—an effect rarely seen when these medications are used for other indications.[53,98] Canakinumab had a 78% response rate compared to 22% response rate for anakinra. Canakinumab also had a more favorable safety profile.[90] Partial response to conventional disease-modifying antirheumatic drugs (eg, methotrexate and azathioprine) have also been reported in some case series, and TNF inhibitors do not appear to be effective.[95,97,98] B-cell depleting therapies should be avoided as these medications are not effective in patients with VEXAS syndrome and can cause prolonged B-cell depletion and immune deficiency. A phase 2 study assessing pacritinib, a small molecule tyrosine kinase inhibitor, in patients with VEXAS syndrome is currently recruiting (NCT06782373).

Comparative trials of JAK inhibitors, anti-IL-6R, and IL-1-directed therapies, have not been conducted, and cohort studies comparing response rates are prone to selection bias, making it difficult to draw conclusions about the most effective treatment for systemic inflammation in VEXAS syndrome.[53,95,97] Although some studies have shown efficacy of these agents in decreasing daily prednisone dose, other studies have not shown a steroid-sparing effect.[94,97] In some retrospective series, JAK inhibitors or anti-IL-6R have been reported to have higher efficacy than other agents.[53,95] In a longitudinal study of patients with VEXAS syndrome, neither tocilizumab nor JAK inhibitors were reported to have a clinically meaningful reduction (<5 mg/day difference) in steroid exposure at 1 year after initiation.[2] Perhaps most importantly, treatment with tocilizumab or JAK inhibitors does not appear to alter the trajectory of progressive bone marrow failure in patients with VEXAS syndrome and does not reduce the *UBA1*^{mut} burden.[2,84,94] Prospective

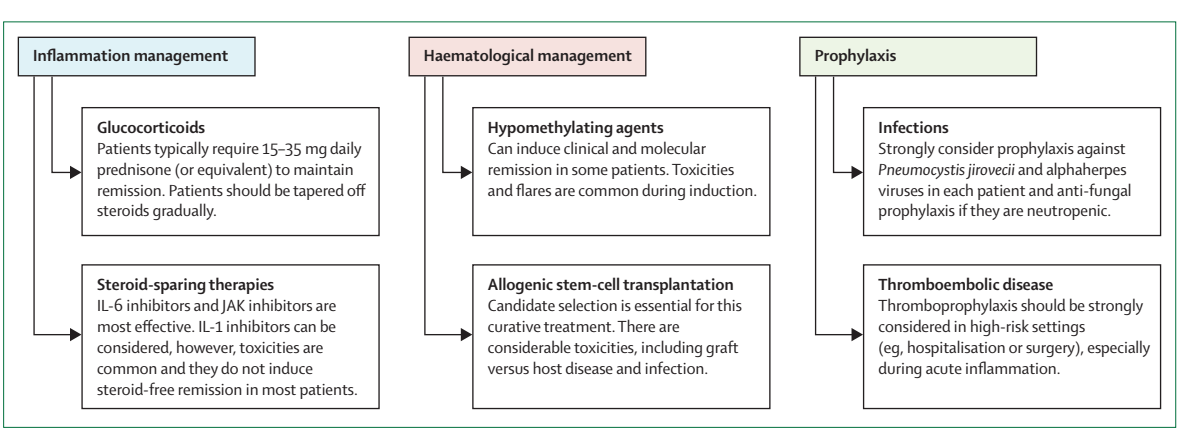

Figure 3: **Management considerations for patients with VEXAS syndrome**
Recommendations to manage the haematological, inflammatory, and prophylactic manifestations of VEXAS syndrome. VEXAS=vacuoles, E1 enzyme, X-linked, autoinflammatory, somatic.

	Dosing regimens	Most common or severe toxicities	Management
Azacitidine (hypomethylating agent)[80]	75 mg/m² intravenously or subcutaneously for 7 days,[81] consider dose reduction to 75 mg/m² intravenously or subcutaneously for 5 days in people who are at high risk or if toxicity is present.[82]	Clinically significant cytopenias (anaemia, thrombocytopenia, and neutropenia); infection; subcutaneous injection site reactions; and disease flare in the first 2–3 cycles.	Closely monitor patients for cytopenias; monitor patients for neutropenia-related and atypical infections; and consider escalation of glucocorticoids for the first 1–3 cycles.
Ruxolitinib (JAK1, JAK2, and TYK2 inhibitors)[83]	5–20 mg twice daily,[84,85] with doses titrated based on haematological toxicity.	Cytopenias (anaemia most common); infection (viral [eg, varicella zoster virus], bacterial, fungal, and atypical mycobacterial); non-melanoma skin cancers; and although thrombosis is not reported, it might be a class effect of JAK inhibitors.	Consider use of erythropoietin if anaemia is dose-limiting; administer antiviral prophylaxis; and monitor for atypical infection.
Anti-IL-6 (tocilizumab[86] or sarilumab)[87]	Tocilizumab: 4–8 mg/kg intravenously every 4 weeks (preferred) or 162 mg weekly subcutaneously; sarilumab: 200 mg subcutaneously every 2 weeks.[2]	Cytopenia (neutropenia and thrombocytopenia); infection (viral [eg, varicella zoster virus], bacterial, fungal, and atypical mycobacterial); infusion and subcutaneous injection site reactions; diverticulitis and bowel perforation; and hepatic toxicity.	A degree of neutropenia (absolute neutrophil count >0·75 × 10⁹/L) and thrombocytopenia (platelets 50 × 10⁹/L) is tolerated in patients with VEXAS syndrome; consider giving intravenous formulation to avoid subcutaneous reactions; and avoid administering anti-IL-6 if patient has history of diverticulitis.
Anti-IL-1 (anakinra[88] or canakinumab [IL-1b][89])	Canakinumab: 150–300 mg subcutaneous every 4 weeks (preferred);[90] anakinra: 100–200 mg subcutaneous daily[90]	Neutropenia (anakinra); subcutaneous injection site reactions (especially anakinra); infusion reactions; and infection (mainly bacterial and viral, but possibly atypical).	A degree of neutropenia (absolute neutrophil count >0·75 × 10⁹/L) is tolerated in patients with VEXAS syndrome. Consider use of canakinumab due to severe subcutaneous reactions with anakinra.
Other JAK inhibitors (upadacitinib [selective JAK1],[91] tofacitinib [JAK1/3],[92] or baricitinib [JAK1/2][93])	Upadacitinib: 15–45 mg daily with a median utilised dose in VEXAS of 15 mg;[85] tofacitinib: 5–10 mg daily;[85] baricitinib: 2 mg daily.[85]	Cytopenias; infection (viral [eg, varicella zoster virus], bacterial, fungal, and atypical mycobacterial); hepatic toxicity; non-melanoma skin cancers; thrombosis; and major adverse cardiovascular events.	Administer antiviral prophylaxis and monitor for atypical infection. Caution to be used if patient has history of thrombosis.

VEXAS=vacuoles, E1 enzyme, X-linked, autoinflammatory, somatic.

Table: **Steroid-sparing therapies commonly used for VEXAS syndrome**

comparative clinical trials using immune-targeting therapies in patients with VEXAS syndrome are needed to properly discern differences in clinical effect and toxicity.

Targeting the mutated clone with hypomethylating agents or allogeneic stem-cell transplant

As with any clonal haematopoietic disease, targeting or eliminating the mutated cells offers promising therapeutic potential. Haematopoietic cell transplant and hypomethylating agents have shown both molecular and clinical remission in patients with VEXAS syndrome.

Hypomethylating agents, particularly azacytidine, are one of the most effective therapies for VEXAS syndrome with canonical *UBA1*^{mut}, especially in patients with VEXAS syndrome and myelodysplastic syndrome. A phase II prospective trial of azacytidine conducted on patients with steroid-refractory or steroid-dependent systemic autoinflammatory disorders (along with myelodysplastic syndrome or chronic myelomonocytic leukaemia), retrospectively identified that 41% of cases were in fact VEXAS syndrome. In this large-scale report, clinical efficacy was reported for six cycles of standard dosing of azacytidine (75 mg/m² daily for 7 days every 4 weeks), with nine (65%) of 12 patients with VEXAS syndrome achieving complete resolution of disease manifestations.[99] Multiple case series have validated the efficacy signal of azacytidine and highlighted the disease-modifying capability, evidenced by a substantial reduction in the population of *UBA1*^{mut} cells in some cases.[43,82,100]

A large multicentre, retrospective study involving 88 genetically confirmed patients with VEXAS syndrome—all presenting with systemic inflammation and 70 with a concurrent diagnosis of myelodysplastic syndrome—has established azacytidine as an effective therapy for refractory inflammation and persistent cytopenia.[81] Inflammatory response was reached in 34 (41%) patients after 6 months of azacytidine treatment, further improving to 36 (54%) patients at 12 months, allowing for glucocorticoid reduction in prednisone equivalents to less than 10 mg daily in complete responders, which comprised 25 (30%) patients at 6 months and 39 (48%) patients at 12 months. Haematological responses, including transfusion independence, were reported in 51 patients treated. Notably, molecular response, defined as a reduction in *UBA1*^{mut} VAF by 25% or more, was reported in 26 (65%) of 40 evaluated patients, with approximately 50% reaching a *UBA1*^{mut} VAF less than 2%. Molecular response was associated with clinical inflammatory and haematological response.

Although co-occurring mutations in epigenetic regulators, such as *DNMT3A* and *TET2*, are common in VEXAS syndrome, current data are insufficient to identify any association between these mutations and response to hypomethylating agents. Azacytidine is standard treatment for patients at high risk of myelodysplastic syndrome; however, responses are typically not associated with a reduction in clonal burden. Whether azacytidine directly targets *UBA1*^{mut} or alters the heightened

inflammatory environment thereby decreasing clonal fitness, remains to be elucidated. Both clinical relapse and prolonged remissions have been reported with ongoing therapy and after discontinuation of azacytidine, as well as prolonged remissions in patients with no detectable *UBA1* by standard clinical next-generation sequencing testing.[81,101] These observations raise two crucial questions that require resolution through long-term prospective follow-up and clinical trials: what is the optimal dosing and duration of treatment, and what are the biomarkers that predict response and resistance?

Toxicities associated with azacytidine treatment are often dose-limiting in myelodysplastic syndrome and are similarly observed in VEXAS syndrome, particularly during the initial treatment cycles. Early severe infections, which can sometimes be fatal, have been reported in patients with VEXAS syndrome.[81,101] Given the emergence of several effective medical therapies and the absence of a standardised treatment algorithm, therapy selection for patients in our VEXAS multidisciplinary clinic is guided by the disease phenotype—such as refractory systemic inflammation, glucocorticoid dependence, bone marrow failure, myelodysplastic syndrome, immunodeficiency with opportunistic infections, thrombosis, co-morbidities, and anticipated treatment toxicities, particularly the risks of infection and cytopenia.[53]

Haematopoietic cell transplantation offers an effective approach for VEXAS syndrome; however, it is limited to a specific group of patients due to the typical disease presentation at older than 50 years when patients are more likely to have comorbidities, reduced performance status, and limited donor availability. The primary indication for haematopoietic cell transplantation is clinically significant and persistent cytopenia non-responsive to medical therapy, although some patients with refractory-inflammatory disease have undergone successful transplantation.[102–104]

In a prospective study involving ten patients who received reduced-intensity conditioning, engraftment was achieved, and *UBA1*^{mut} was eradicated in all patients with concurrent clinical remission. Although mixed chimerism was common, it was not associated with disease recurrence or graft failure.[105] In a series reported by the European Society for Blood and Marrow Transplantation, 19 patients, mostly with concomitant myelodysplastic syndrome, underwent haematopoietic cell transplant after not responding to medical therapies, including azacitidine in eight (50%) patients.[106] Varying conditioning regimens, donors, and graft versus host disease (GVHD) prophylaxis regimens were utilised, and most patients reached full chimerism with rapid neutrophil and platelet engraftment. With a median follow-up of more than 1 year, 58% of patients experienced acute GVHD (five patients were grade 2–4), but no relapse was reported for VEXAS syndrome.

The inherent toxicities of haematopoietic cell transplant, including infections, GVHD, and resultant mortality, are important considerations as transplant is optimised for this largely non-malignant condition.[107] The timing of haematopoietic cell transplant, patient and donor selection, and optimal conditioning and GVHD prophylaxis adapted to disease phenotype, needs to be better defined in prospective clinical trials. An ongoing prospective phase II clinical trial (NCT05027945), using a fludarabine–busulfan reduced-intensity conditioning regimen at the National Institutes of Health could provide further insights.

Other management considerations in VEXAS syndrome

Supportive care, particularly infectious prophylaxis, is crucial. A considerable reduction in the occurrence of *P jirovecii* pneumonia and varicella zoster virus reactivation was reported with prophylactic antimicrobials, leading to a standard recommendation using prophylaxis to prevent these life-threatening infections.[41]

For patients with clinically significant anaemia, transfusion support and the use of erythroid stimulating agents have been reported to be effective.[108] Venous thromboembolism is treated according to standard guidelines, with extended-duration anticoagulation preferred due to ongoing risks of recurrence linked to systemic inflammation, male sex, glucocorticoid use, and subacute or chronic immobilisation. Periodic risk assessments for bleeding are particularly important in patients with cytopenia. Although robust evidence for thromboprophylaxis in VEXAS is poor, its implementation is advisable in high-risk settings, such as hospitalisation or surgery, due to the incidence of venous thromboembolism, unless the potential risks outweigh the benefits.[78] The role of ambulatory venous thromboembolism prophylaxis (ie, during a non-hospitalised acute flare) is unknown and requires further study. Currently, there is no evidence to suggest deviations from standard therapies for patients with VEXAS syndrome diagnosed with other haematological malignancies, including acute myeloid leukaemia, chronic myeloid leukaemia, myeloproliferative neoplasms, and multiple myeloma.

Conclusion

Beyond the discovery of a new disease that is remarkably prevalent and life-threatening, VEXAS syndrome illustrates the potential causal role that somatic variants might have in non-malignant conditions. Acquired mutations in blood or solid organs might underlie a spectrum of single-organ and systemic diseases. Defining complex inflammatory diseases based on molecular characterisation of disease rather than patterns of clinical features will likely continue to reshape disease taxonomy in rheumatology and other related medical specialties for many decades.

Although much has been uncovered in the 5 years since the discovery of VEXAS syndrome, there remain

many unknowns in terms of pathophysiology, diagnostics, and therapeutics. The origins and clonal selection of *UBA1* mutations, and the precise mechanisms underlying the resultant systemic autoinflammatory effect, remain poorly understood. Most published clinical data are retrospective, and there are currently no approved drugs from a regulatory body for VEXAS syndrome, although there are two prospective clinical trials underway. In August, 2025, the International VEXAS Working Group Expert Panel proposed the first formal international consensus guidance for VEXAS syndrome, incorporating both diagnostics and clinical management.[48] However, overall treatment outcomes remain inadequate with patients remaining dependent on chronic glucocorticoids, highlighting the need for further research.

Contributors

All authors contributed to the study design, literature search, writing of the manuscript, and approval of the final version.

Declaration of interests

We declare no competing interests.

Acknowledgments

This research was funded by the Intramural Research Program of the National Heart, Lung, and Blood Institute and the National Institute of Arthritis and Musculoskeletal and Skin Diseases. The findings and conclusions presented in this Review are those of the authors and do not necessarily reflect the views of the National Institutes of Health or the US Department of Health and Human Services. Photographs in figure 2 were provided by the National Institutes of Health VEXAS Cohort.

References

1 Beck DB, Ferrada MA, Sikora KA, et al. Somatic mutations in *UBA1* and severe adult-onset autoinflammatory disease. *N Engl J Med* 2020; **383:** 2628–38.

2 Turturice BA, Fike A, Patel BA, et al. Disease trajectories and glucocorticoid exposure in VEXAS syndrome treated with cytokine-directed therapies. *Ann Rheum Dis* 2025; published online June 17. https://doi.org/10.1016/j.ard.2025.05.021.

3 Georgin-Lavialle S, Terrier B, Guedon AF, et al. Further characterization of clinical and laboratory features in VEXAS syndrome: large-scale analysis of a multicentre case series of 116 French patients. *Br J Dermatol* 2022; **186:** 564–74.

4 Montes D, Hanson AC, Langenfeld HE, et al. Developing efficient predictive models for the diagnosis of VEXAS syndrome. *Semin Arthritis Rheum* 2025; **74:** 152796.

5 Echerbault R, Bourguiba R, Georgin-Lavialle S, Lavigne C, Ravaiau C, Lacombe V. Comparing clinical features between males and females with VEXAS syndrome: data from literature analysis of patient reports. *Rheumatology* 2024; **63:** 2694–700.

6 Ferrada MA, Savic S, Cardona DO, et al. Translation of cytoplasmic UBA1 contributes to VEXAS syndrome pathogenesis. *Blood* 2022; **140:** 1496–506.

7 Gutierrez-Rodrigues F, Kusne Y, Fernandez J, et al. Spectrum of clonal hematopoiesis in VEXAS syndrome. *Blood* 2023; **142:** 244–59.

8 Ferrada MA, Sikora KA, Luo Y, et al. Somatic mutations in UBA1 define a distinct subset of relapsing polychondritis patients with VEXAS. *Arthritis Rheumatol* 2021; **73:** 1886–95.

9 Gutierrez-Rodrigues F, Wells KV, Jones AI, et al. Clonal haematopoiesis across the age spectrum of vasculitis patients with Takayasu's arteritis, ANCA-associated vasculitis and giant-cell arteritis. *Ann Rheum Dis* 2024; **83:** 508–17.

10 Sirenko M, Bernard E, Creignou M, et al. Molecular and clinical presentation of UBA1-mutated myelodysplastic syndromes. *Blood* 2024; **144:** 1221–29.

11 Beck DB, Bodian DL, Shah V, et al. Estimated prevalence and clinical manifestations of UBA1 variants associated with VEXAS syndrome in a clinical population. *JAMA* 2023; **329:** 318–24.

12 Corty RW, Brogan J, Byram K, Springer J, Grayson PC, Bick AG. VEXAS-defining UBA1 somatic variants in 245 368 diverse individuals in the NIH All Of Us Cohort. *Arthritis Rheumatol* 2024; **76:** 942–48.

13 Anderson M, Ercelen D, Richardson A, et al. Clinical manifestations of VEXAS syndrome across a broad spectrum of uba1 mutation burden. *Arthritis Rheunatol* 2025; published online July 21. https://doi.org/10.1002/art.43327.

14 Beck DB, Werner A, Kastner DL, Aksentijevich I. Disorders of ubiquitylation: unchained inflammation. *Nat Rev Rheumatol* 2022; **18:** 435–47.

15 Handley-Gearhart PM, Stephen AG, Trausch-Azar JS, Ciechanover A, Schwartz AL. Human ubiquitin-activating enzyme, E1. Indication of potential nuclear and cytoplasmic subpopulations using epitope-tagged cDNA constructs. *J Biol Chem* 1994; **269:** 33171–78.

16 Grenfell SJ, Trausch-Azar JS, Handley-Gearhart PM, Ciechanover A, Schwartz AL. Nuclear localization of the ubiquitin-activating enzyme, E1, is cell-cycle-dependent. *Biochem J* 1994; **300:** 701–08.

17 Stephen AG, Trausch-Azar JS, Ciechanover A, Schwartz AL. The ubiquitin-activating enzyme E1 is phosphorylated and localized to the nucleus in a cell cycle-dependent manner. *J Biol Chem* 1996; **271:** 15608–14.

18 Nouspikel T, Hanawalt PC. Impaired nucleotide excision repair upon macrophage differentiation is corrected by E1 ubiquitin-activating enzyme. *Proc Natl Acad Sci USA* 2006; **103:** 16188–93.

19 Collins JC, Magaziner SJ, English M, et al. Shared and distinct mechanisms of UBA1 inactivation across different diseases. *EMBO J* 2024; **43:** 1919–46.

20 Dikic I, Schulman BA. An expanded lexicon for the ubiquitin code. *Nat Rev Mol Cell Biol* 2023; **24:** 273–87.

21 Schulman BA, Harper JW. Ubiquitin-like protein activation by E1 enzymes: the apex for downstream signalling pathways. *Nat Rev Mol Cell Biol* 2009; **10:** 319–31.

22 Poulter JA, Collins JC, Cargo C, et al. Novel somatic mutations in UBA1 as a cause of VEXAS syndrome. *Blood* 2021; **137:** 3676–81.

23 Martinez Rodriguez A, Chang L, Rowczenio D, et al. Mapping VEXAS-associated and rare UBA1 variants in the United Kingdom: insights from patient cohorts and the general population. *Br J Haematol* 2025; published online May 25. https://doi.org/10.1111/bjh.20176.

24 Sakuma M, Blombery P, Meggendorfer M, et al. Novel causative variants of VEXAS in UBA1 detected through whole genome transcriptome sequencing in a large cohort of hematological malignancies. *Leukemia* 2023; **37:** 1080–91.

25 Faurel A, Heiblig M, Kosmider O, et al. Recurrent mutations of the active adenylation domain of UBA1 in atypical form of VEXAS syndrome. *HemaSphere* 2023; **7:** e868.

26 Stiburkova B, Pavelcova K, Belickova M, et al. Novel somatic UBA1 variant in a patient with VEXAS syndrome. *Arthritis Rheumatol* 2023; **75:** 1285–90.

27 Al-Hakim A, Kulasekararaj A, Norouzi M, et al. S56F UBA1 variant is associated with haematological predominant subtype of VEXAS. *Br J Haematol* 2023; **203:** 331–35.

28 Molteni R, Fiumara M, Campochiaro C, et al. Mechanisms of hematopoietic clonal dominance in VEXAS syndrome. *Nat Med* 2025; **31:** 1911–24.

29 Obiorah IE, Patel BA, Groarke EM, et al. Benign and malignant hematologic manifestations in patients with VEXAS syndrome due to somatic mutations in UBA1. *Blood Adv* 2021; **5:** 3203–15.

30 Olteanu H, Patnaik M, Koster MJ, et al. Comprehensive morphologic characterization of bone marrow biopsy findings in a large cohort of patients with VEXAS syndrome: a single-institution longitudinal study of 111 bone marrow samples from 52 patients. *Am J Clin Pathol* 2024; **161:** 609–24.

31 Patel N, Dulau-Florea A, Calvo KR. Characteristic bone marrow findings in patients with UBA1 somatic mutations and VEXAS syndrome. *Semin Hematol* 2021; **58:** 204–11.

32 Mizumaki H, Gao S, Wu Z, et al. In depth transcriptomic profiling defines a landscape of dysfunctional immune responses in patients with VEXAS syndrome. *Nat Commun* 2025; **16:** 4690.

33 Wu Z, Gao S, Gao Q, et al. Early activation of inflammatory pathways in UBA1-mutated hematopoietic stem and progenitor cells in VEXAS. *Cell Rep Med* 2023; **4:** 101160.

34 Ganesan S, Murray RM, Sotelo J, et al. Single-cell genotype-phenotype mapping identifies therapeutic vulnerabilities in VEXAS syndrome. *bioRxiv* 2024: 2024.05.19.594376.

35 Ganesan S, Murray R, Sotelo J, et al. genotype-phenotype mapping via single-cell multi- omics identifies therapeutic vulnerabilities in VEXAS syndrome. *Blood* 2023; **142** (suppl 1)**:** 142.

36 Grolleau C, Battistella M, Zakine E, et al. Inflammatory signatures in VEXAS syndrome, myelodysplasia cutis, and sweet syndrome. *JAMA Dermatol* 2025; **161:** 538–43.

37 Kosmider O, Possémé C, Templé M, et al. VEXAS syndrome is characterized by inflammasome activation and monocyte dysregulation. *Nat Commun* 2024; **15:** 910.

38 Austermann J, Spiekermann C, Roth J. S100 proteins in rheumatic diseases. *Nat Rev Rheumatol* 2018; **14:** 528–41.

39 Adachi S, Kirino Y, Higashitani K, et al. Targeting enhanced cell death represents a potential therapeutic strategy for VEXAS syndrome. *Rheumatol Adv Pract* 2024; **8:** rkae065.

40 Ali SB, Gurnari C. Infections in VEXAS syndrome: a systematic review of the literature. *Curr Res Transl Med* 2025; **73:** 103524.

41 Czech M, Cuellar-Rodriguez J, Patel BA, et al. Opportunistic infections, mortality risk, and prevention strategies in patients with vacuoles, E1 enzyme, X-linked, autoinflammatory, somatic (VEXAS) syndrome. *Open Forum Infect Dis* 2024; **11:** ofae405.

42 de Valence B, Delaune M, Nguyen Y, et al. Serious infections in patients with VEXAS syndrome: data from the French VEXAS registry. *Ann Rheum Dis* 2024; **83:** 372–81.

43 Wolff L, Caratsch L, Lötscher F, et al. VEXAS syndrome: a Swiss national retrospective cohort study. *Swiss Med Wkly* 2024; **155:** 3879.

44 Kirino Y, Maeda A, Asano T, et al. Low remission rates and high incidence of adverse events in a prospective VEXAS syndrome registry. *Rheumatology* 2024; **64:** 3872–78.

45 Shin D, Mukherjee R, Liu Y, et al. Regulation of phosphoribosyl-linked serine ubiquitination by deubiquitinases DupA and DupB. *Mol Cell* 2020; **77:** 164–79.e6.

46 Wan M, Sulpizio AG, Akturk A, et al. Deubiquitination of phosphoribosyl-ubiquitin conjugates by phosphodiesterase-domain-containing *Legionella* effectors. *Proc Natl Acad Sci USA* 2019; **116:** 23518–26.

47 Li J, Chai QY, Liu CH. The ubiquitin system: a critical regulator of innate immunity and pathogen-host interactions. *Cell Mol Immunol* 2016; **13:** 560–76.

48 Mekinian AM, Georgin-Lavaille S, Ferrada MA, et al. American College of Rheumatology Guidance Statement for diagnosis and management of VEXAS developed by the International VEXAS Working Group Expert Panel. *Arthritis Rheumatol* 2025; published online Aug 11. https://doi.org/10.1002/art.43287.

49 Tan IJ, Ferrada MA, Ahmad S, et al. Skin manifestations of VEXAS syndrome and associated genotypes. *JAMA Dermatol* 2024; **160:** 822–29.

50 Hines AS, Mohandesi NA, Lehman JS, et al. Cutaneous involvement in VEXAS syndrome: clinical and histopathologic findings. *Int J Dermatol* 2023; **62:** 938–45.

51 Zakine È, Papageorgiou L, Bourguiba R, et al. Clinical and pathological features of cutaneous manifestations in VEXAS syndrome: a multicenter retrospective study of 59 cases. *J Am Acad Dermatol* 2023; **88:** 917–20.

52 Borie R, Debray MP, Guedon AF, et al. Pleuropulmonary manifestations of vacuoles, E1 enzyme, X-linked, autoinflammatory, somatic (VEXAS) syndrome. *Chest* 2023; **163:** 575–85.

53 Al-Hakim A, Trikha R, Phyu Htut EE, et al. Treatment outcomes in patients with VEXAS syndrome: a retrospective cohort study. *Lancet Rheumatol* 2025; **7:** e472–84.

54 van der Made CI, Potjewijd J, Hoogstins A, et al. Adult-onset autoinflammation caused by somatic mutations in UBA1: a Dutch case series of patients with VEXAS. *J Allergy Clin Immunol* 2022; **149:** 432–439.e4.

55 Mascaro JM, Rodriguez-Pinto I, Poza G, et al. Spanish cohort of VEXAS syndrome: clinical manifestations, outcome of treatments and novel evidences about *UBA1* mosaicism. *Ann Rheum Dis* 2023; **82:** 1594–605.

56 Casal Moura M, Baqir M, Tandon YK, et al. Pulmonary manifestations in VEXAS syndrome. *Respir Med* 2023; **213:** 107245.

57 Robert M, Mathian A, Lacombe V, et al. Nonischemic cardiac manifestations in VEXAS syndrome. *JAMA Netw Open* 2024; **7:** e2450251.

58 García-Escudero P, López-Gómez M, López BM, et al. VEXAS syndrome through a rheumatologist's lens: insights from a Spanish national cohort. *Rheumatology* 2025; **64:** 3747–55.

59 Vitale A, Caggiano V, Martin-Nares E, et al. Orbital/ocular inflammatory involvement in VEXAS syndrome: data from the international AIDA network VEXAS registry. *Semin Arthritis Rheum* 2024; **66:** 152430.

60 Abumanhal M, Leibovitch I, Zisapel M, Eviatar T, Edel Y, Ben Cnaan R. Ocular and orbital manifestations in VEXAS syndrome. *Eye* 2024; **38:** 1748–54.

61 Sullivan MM, Mead-Harvey C, Sartori-Valinotti JC, et al. Vasculitis associated with VEXAS syndrome. *Rheumatology* 2025; **64:** 3889–94.

62 Mathurin M, Hirsch P, Jachiet V, et al. A clinicopathological description of kidney features in VEXAS syndrome. *Kidney Int Rep* 2024; **10:** 260–64.

63 Al-Hakim A, Goldberg S, Gaillard S, Heiblig M, Beck DB, Savic S. Clinical features in VEXAS syndrome: a systematic review. *Rheumatology* 2025; **64:** 5217–29.

64 Philip R, Cadro V, Aouba A, Chantepie S, Bracquemart C, Dumont A. VEXAS syndrome: a new mimicker of idiopathic multicentric Castleman disease. *Joint Bone Spine* 2024; **91:** 105731.

65 Khitri MY, Guedon AF, Georgin-Lavialle S, et al. Comparison between idiopathic and VEXAS-relapsing polychondritis: analysis of a French case series of 95 patients. *RMD Open* 2022; **8:** e002255.

66 de Valence B, Delaune M, Nguyen Y, et al. Serious infections in patients with VEXAS syndrome: data from the French VEXAS registry. *Ann Rheum Dis* 2024; **83:** 372–81.

67 Lacombe V, Hadjadj J, Georgin-Lavialle S, Lavigne C, Geneviève F, Kosmider O. Vacuoles in bone marrow progenitors: VEXAS syndrome and beyond. *Lancet Haematol* 2024; **11:** e160–67.

68 Cherniawsky H, Friedmann J, Nicolson H, et al. VEXAS syndrome: a review of bone marrow aspirate and biopsies reporting myeloid and erythroid precursor vacuolation. *Eur J Haematol* 2023; **110:** 633–38.

69 Gurnari C, Pagliuca S, Durkin L, et al. Vacuolization of hematopoietic precursors: an enigma with multiple etiologies. *Blood* 2021; **137:** 3685–89.

70 Rabut A, Jasserand L, Richard C, et al. Quantitative assessment of vacuolization of myeloid precursors in VEXAS syndrome. *HemaSphere* 2023; **7:** e828.

71 Kosmider O, Possémé C, Templé M, et al. VEXAS syndrome is characterized by inflammasome activation and monocyte dysregulation. *Nat Commun* 2024; **15:** 910.

72 Rodrigues F, Hardouin G, El Hoss S, et al. Vexas syndrome is a new cause of p53-mediated erythroblastopenia. *Blood* 2024; **144** (suppl 1)**:** 36.

73 Mizumaki H, Gao S, Wu Z, et al. In depth transcriptomic profiling defines a landscape of dysfunctional immune responses in patients with VEXAS syndrome. *Nat Commun* 2025; **16:** 4690.

74 Al-Hakim A, Kulasekararaj A, Norouzi M, et al. S56F UBA1 variant is associated with haematological predominant subtype of VEXAS. *Br J Haematol* 2023; **203:** 331–35.

75 Sakuma M, Blombery P, Meggendorfer M, et al. Novel causative variants of VEXAS in UBA1 detected through whole genome transcriptome sequencing in a large cohort of hematological malignancies. *Leukemia* 2023; **37:** 1080–91.

76 Kyle RA, Therneau TM, Rajkumar SV, et al. Prevalence of monoclonal gammopathy of undetermined significance. *N Engl J Med* 2006; **354:** 1362–69.

77 Dulau-Florea A, Braylan RC, Ding Y, et al. Clonal bone marrow plasma cells are common in patients with VEXAS syndrome. *Blood* 2023; **142** (suppl 1)**:** 4681.

78 Kusne Y, Ghorbanzadeh A, Dulau-Florea A, et al. Venous and arterial thrombosis in patients with VEXAS syndrome. *Blood* 2024; **143:** 2190–200.

79 Groarke EM, Dulau-Florea AE, Kanthi Y. Thrombotic manifestations of VEXAS syndrome. *Semin Hematol* 2021; **58:** 230–38.

80 US Food and Drug Administration. Prescribing information for vidaza. 2022. https://www.accessdata.fda.gov/drugsatfda_docs/label/2022/050974s034lbl.pdf (accessed Sept 30, 2025).

81 Jachiet V, Kosmider O, Beydon M, et al. Efficacy and safety of azacitidine for VEXAS syndrome: a large-scale retrospective study from FRENVEX. *Blood* 2025; **146:** 1450–61.

82 Trikha R, Kong KL, Galloway J, et al. De-escalation of corticosteroids and clonal remission in *UBA1* mutation-driven VEXAS syndrome with 5-azacytidine. *Haematologica* 2024; **109:** 3431–34.

83 US Food and Drug Administration. Prescribing information for jakafi. 2011. https://www.accessdata.fda.gov/drugsatfda_docs/label/2022/050974s034lbl.pdf (accessed Sept 30, 2025).

84 Heiblig M, Ferrada MA, Koster MJ, et al. Ruxolitinib is more effective than other JAK inhibitors to treat VEXAS syndrome: a retrospective multicenter study. *Blood* 2022; **140:** 927–31.

85 Bahramian S, Fazeli P, Rafati A, et al. JAK inhibitors for treatment of VEXAS Syndrome: a systematic review of 186 cases. *Dermatol Res Pract* 2025; **2025:** 9127126.

86 US Food and Drug Administration. Prescribing information for actemera. 2024. https://www.accessdata.fda.gov/drugsatfda_docs/label/2022/050974s034lbl.pdf (accessed Sept 30, 2025).

87 US Food and Drug Administration. Prescribing information for kevzara. 2017. https://www.accessdata.fda.gov/drugsatfda_docs/label/2022/050974s034lbl.pdf (accessed Sept 30, 2025).

88 US Food and Drug Administration. Prescribing information for kineret. 2012. https://www.accessdata.fda.gov/drugsatfda_docs/label/2022/050974s034lbl.pdf (accessed Sept 30, 2025).

89 US Food and Drug Administration. Prescribing information for ilaris. 2016. https://www.accessdata.fda.gov/drugsatfda_docs/label/2022/050974s034lbl.pdf (accessed Sept 30, 2025).

90 Eviatar T, Capelusnik D, Campochiaro C, et al. Comparative efficacy and safety of anakinra and canakinumab in patients with VEXAS syndrome—an international multicenter study. *Arthritis Rheumatol* 2025; published online Sept 22. https://doi.org/10.1002/art.43384.

91 US Food and Drug Administration. Prescribing information for rinvoq. 2023. https://www.accessdata.fda.gov/drugsatfda_docs/label/2023/211675s019lbl.pdf (accessed Sept 30, 2025).

92 US Food and Drug Administration. Prescribing information for xeljanz. 2020. https://www.accessdata.fda.gov/drugsatfda_docs/label/2020/203214s026lbl.pdf (accessed Sept 30, 2025).

93 US Food and Drug Administration. Prescribing information for olumiant. 2020. https://www.accessdata.fda.gov/drugsatfda_docs/label/2022/050974s034lbl.pdf (accessed Sept 30, 2025).

94 Johansen MM, El Fassi D, Nielsen CTH, Krintel SB, Graudal N, Hansen JW. Treatment experiences with focus on IL-6R inhibition in patients with VEXAS syndrome and a case of remission with azacytidine treatment. *Rheumatology* 2025; **64:** 826–30.

95 Hadjadj J, Nguyen Y, Mouloudj D, et al. Efficacy and safety of targeted therapies in VEXAS syndrome: retrospective study from the FRENVEX. *Ann Rheum Dis* 2024; **83:** 1358–67.

96 Bourbon E, Heiblig M, Gerfaud Valentin M, et al. Therapeutic options in VEXAS syndrome: insights from a retrospective series. *Blood* 2021; **137:** 3682–84.

97 Vitale A, Caggiano V, Leone F, et al. Efficacy and safety profile of biotechnological agents and Janus kinase inhibitors in VEXAS syndrome: data from the international AIDA Network VEXAS registry. *Front Pharmacol* 2025; **16:** 1462254.

98 Vitale A, Leone F, Caggiano V, et al. Efficacy and safety of conventional disease-modifying antirheumatic drugs in VEXAS syndrome: real-world data from the international AIDA network. *Front Pharmacol* 2025; **16:** 1539756.

99 Mekinian A, Zhao LP, Chevret S, et al. A phase II prospective trial of azacitidine in steroid-dependent or refractory systemic autoimmune/inflammatory disorders and VEXAS syndrome associated with MDS and CMML. *Leukemia*; **36:** 2739–42.

100 Raaijmakers MHGP, Hermans M, Aalbers A, et al. Azacytidine treatment for VEXAS syndrome. *HemaSphere* 2021; **5:** e661.

101 Aalbers AM, van Daele PLA, Dalm VASH, Valk PJM, Raaijmakers MHGP. Long-term genetic and clinical remissions after cessation of azacitidine treatment in patients with VEXAS syndrome. *HemaSphere* 2024; **8:** e129.

102 Dias AL, Groarke EM, Hickstein D, Patel B. Role of allogeneic hematopoietic cell transplantation in VEXAS syndrome. *Ann Hematol* 2024; **103:** 4427–36.

103 Al-Hakim A, Poulter JA, Mahmoud D, et al. Allogeneic haematopoietic stem-cell transplantation for VEXAS syndrome: UK experience. *Br J Haematol* 2022; **199:** 777–81.

104 Diarra A, Duployez N, Fournier E, et al. Successful allogeneic hematopoietic stem-cell transplantation in patients with VEXAS syndrome: a 2-center experience. *Blood Adv* 2022; **6:** 998–1003.

105 Mangaonkar AA, Langer KJ, Lasho TL, et al. Reduced intensity conditioning allogeneic hematopoietic stem-cell transplantation in VEXAS syndrome: data from a prospective series of patients. *Am J Hematol* 2023; **98:** E28–31.

106 Gurnari C, Koster L, Baaij L, et al. Allogeneic hematopoietic cell transplantation for VEXAS syndrome: results of a multicenter study of the EBMT. *Blood Adv* 2024; **8:** 1444–48.

107 Mohty R, Reljic T, Abdel-Razeq N, et al. Assessing the efficacy of allogeneic hematopoietic cell transplantation in VEXAS syndrome: results of a systematic review and meta-analysis. *Bone Marrow Transplant* 2024; **59:** 1423–27.

108 Heiblig M, Jachiet V, Hadjadj J, et al. Efficacy of erythroid-stimulating agent and luspatercept in VEXAS syndrome: a multicenter retrospective study by the FRENVEX group. *Hemasphere* 2025, **9:** e70156.

Published by Elsevier Ltd.